

OBSTETRICS

A new minimally invasive treatment for cesarean scar pregnancy and cervical pregnancy



Ilan E. Timor-Tritsch, MD; Ana Monteagudo, MD; Terri-Ann Bennett, MD; Christine Foley, MD; Joanne Ramos, RDMS; Andrea Kaelin Agten, MD

BACKGROUND: Cesarean scar pregnancy and cervical pregnancy are unrelated forms of pathological pregnancies carrying significant diagnostic and treatment challenges, with a wide range of treatment effectiveness and complication rates ranging from 10% to 62%. At times, life-saving hysterectomy and uterine artery embolization are required to treat complications. Based on our previous success with using a single-balloon catheter for the treatment of cesarean scar pregnancy after local injection of methotrexate, we evaluated the use of a double-balloon catheter to terminate the pregnancy while preventing bleeding without any additive treatment. This was a retrospective study.

OBJECTIVES: The objective of the study was to describe the placement of a cervical ripening double-balloon catheter as a novel, minimally invasive treatment in patients with cesarean scar and cervical pregnancies to terminate the pregnancy and at the same time prevent bleeding by compressing the blood supply of the gestational sac.

STUDY DESIGN: Patients with diagnosed, live cervical pregnancy and cesarean scar pregnancy between 6 and 8 weeks' gestation were considered for the office-based treatment. Paracervical block with 1% lidocaine was administered in 3 patients for pain control. Insertion of the catheter and inflation of the upper balloon were done under transabdominal ultrasound guidance. The lower (pressure) balloon was inflated opposite the gestational sac under transvaginal ultrasound guidance. After an hour, the area of the sac was scanned. When fetal cardiac activity was absent and no bleeding was noted, patients were discharged. After 2-3 days, a follow-up appointment

was scheduled for possible catheter removal. Serial ultrasound (US) and serum human chorionic gonadotropin were followed weekly or as needed.

RESULTS: Three live cervical pregnancies and 7 live cesarean scar pregnancies were successfully treated. Median gestational age at treatment was 6 6/7 weeks (range 6 1/7 through 7 4/7 weeks). Patients' acceptance for the double-balloon treatment was high in spite of the initial low abdominal pressure felt at the inflation of the balloons. All but 1 patient noted vaginal spotting at the follow-up appointment. Only 1 patient experienced bleeding of dark blood. The balloons were in place for a median of 3 days (range, 1–5 days). Median time from treatment to the total drop of human chorionic gonadotropin was 49 days (range, 28–97 days).

CONCLUSION: The double balloon is a successful, minimally invasive and well-tolerated single treatment for cervical pregnancy and cesarean scar pregnancy. This simple treatment method has 4 main advantages: it effectively stops embryonic cardiac activity, prevents bleeding complications, does not require any additional invasive therapies, and is familiar to obstetricians-gynecologists who use the same cervical ripening catheters for labor induction. Its wider application, however, has to be validated on a larger patient population.

Key words: cervical pregnancy, cesarean scar pregnancy, cesarean scar pregnancy treatment, double cervical ripening balloon, early pregnancy, ultrasound

Cesarean scar pregnancy, an iatrogenic pathological entity, is a direct consequence of a cesarean delivery when the subsequent pregnancy implants on the scar area or in the dehiscence (niche) left behind by the hysterectomy.

Larsen and Solomon¹ reported the first case of a cesarean scar pregnancy in 1978 and successfully treated the patient with laparotomy, hysterotomic resection, and uterine scar dehiscence repair. Since that time, the incidence is rising,

paralleling the increasing rate of cesarean delivery. The real incidence of cesarean scar pregnancy is unknown; however, some workers in the field set it at 1 in 1800 to 1 in 2500 cases of previous cesarean deliveries.²

In an in-depth review of 751 cases of cesarean scar pregnancies, the literature search yielded a total of 204 publications between 1972 and 2011.³ In that review, 176 articles reported on first-trimester cesarean scar pregnancies, and another 49 articles described the second-trimester placenta accreta, listing the sometimes devastating complications of these 2 pathologies sharing the same histology.⁴ There were 31 described medical, surgical, or radiological treatments, including single or combination therapies.³

Among the 751 treated cesarean scar pregnancies,³ 331 cases (44.1%)

reported complications. A large number of these complications were the result of misdiagnosis, others caused by the treatment method applied. The most severe and notorious complication was bleeding at or after the applied treatment. Even the treatment method with the least and the most benign complications (eg, intragestational injection of methotrexate or KCl) encountered 1 complication in 10 treatments.³

We previously described the adjuvant treatment of a single Foley balloon insertion and inflation immediately following local, intragestational injection of methotrexate treatment of cesarean scar pregnancy, regardless of presence or absence of bleeding⁵. However, in 3 patients the single balloon was expelled after 1, 2, and 3 days, respectively.⁵

Our hypothesis was, that by using a double-balloon catheter, inflating the

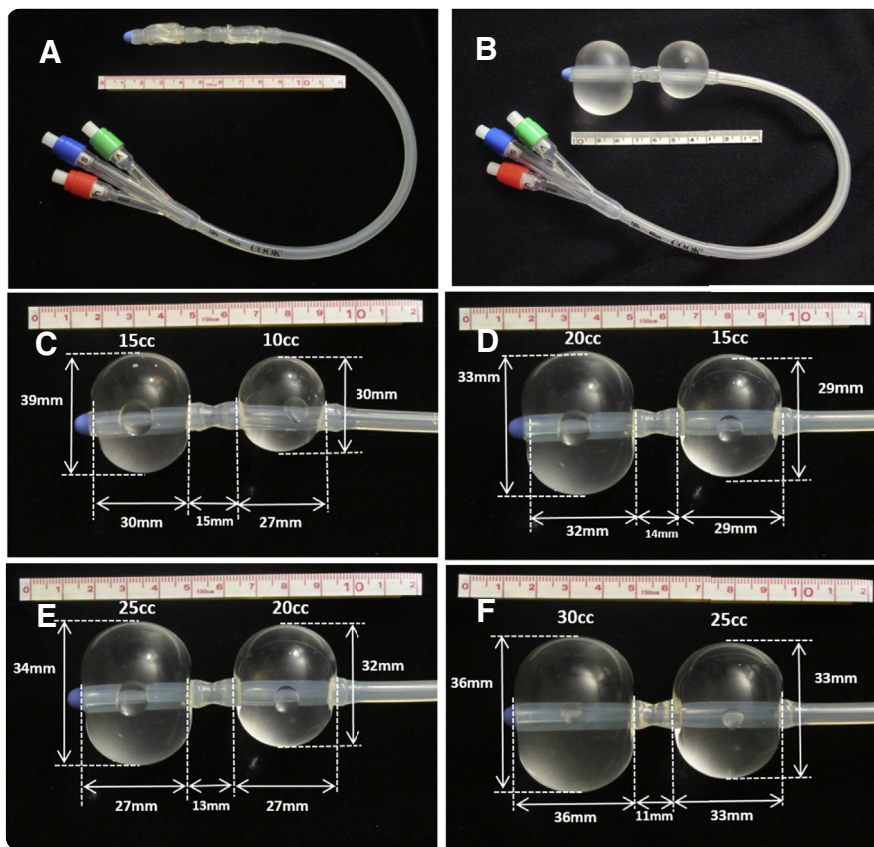
Cite this article as: Timor-Tritsch IE, Monteagudo A, Bennett T-A, et al. A new minimally invasive treatment for cesarean scar pregnancy and cervical pregnancy. *Am J Obstet Gynecol* 2016;215:351.e1-8.

0002-9378/\$36.00

© 2016 Published by Elsevier Inc.
<http://dx.doi.org/10.1016/j.ajog.2016.03.010>

 Click Video under article title in Contents at ajog.org

FIGURE 1
Images of the double-balloon catheter



Images of the double-balloon catheter with measurements of balloon sizes and interballoon distances as a function of volume of saline in them. **A**, The cervical ripening double balloon. The upper balloon is that on the left side of the pictures, close to the tip of the catheter. The 3 ports of the catheter are color coded. **B–F**, In vitro measurements of the upper and lower balloons and their interballoon distance as a function of different combinations of volumes instilled. Balloon volumes, their sizes, and interballoon distances are marked on each picture.

Timor-Tritsch et al. A new treatment for cesarean scar and cervical pregnancies. *Am J Obstet Gynecol* 2016.

upper one in the uterine cavity to serve as an anchor would prevent expulsion of the lower pressure balloon if positioned and inflated opposite the gestational sac to provide the required tamponade.

Our secondary hypothesis was that the pressure the lower balloon exerted upon the gestational sac and its blood supply would be sufficient to stop embryonic cardiac activity while at the same time prevent bleeding. This therapy would be given without any additional intervention, such as a local intragastation injection of methotrexate or KCl or suction aspiration. We also hypothesized that this treatment method will be successful in some cervical pregnancies.

Should the double-balloon placement result in successfully terminating the pregnancy without causing, but rather preventing, hemorrhage from the cervical pregnancy and cesarean scar pregnancy, this new, minimally invasive treatment modality would present a realistic choice managing these 2 dangerous pathologies.

Materials and Methods

This is a retrospective case series of patients diagnosed with cesarean scar pregnancy or cervical pregnancy, between 6 and 8 weeks' gestations, referred to New York University Langone Medical Center with diagnosed or suspected cesarean scar pregnancy and cervical

pregnancy. This study was institutional review board approved (study number s15-01030 by the New York University Review Board).

Preliminary measurement of the inflated double-balloon catheter

To exert the right amount of pressure to stop embryonic cardiac activity to prevent bleeding and balloon expulsion, in vitro experiments were performed prior to the actual use of the double-balloon catheter (Cook Medical; www.Cookmedical.com; number J-CRBS 18400 with stylet). By inflating the upper and lower balloon with increasing volumes of saline, the medical balloon sizes and the interballoon distance was measured. **Figure 1** depicts the catheter and technique of selected experiments.

These measurements show that the upper, intrauterine balloon should be inflated with 30 mL or less fluid. The lower-treatment balloon should be inflated in the cervical canal or close to the internal os with no more than 20 mL fluid. Measurements at the actual use of the catheter were also performed to validate the previously mentioned in vitro measurements.

Diagnostic criteria for cesarean scar pregnancy and cervical pregnancy

In the presence of a positive pregnancy test and in patients with history of previous cesarean delivery, the criteria for a cesarean scar pregnancy were, as published earlier,⁶ the gestational sac and/or placenta were imaged embedded in the hysterotomy scar with a fetal pole and/or yolk sac containing a live embryo; empty uterine cavity and cervical canal; a thin (<3 mm) myometrial layer between the gestational sac/placenta and bladder and the presence of a rich vascular pattern in the area of the cesarean delivery scar and the placenta.

In patients without a previous cesarean delivery, a gestational sac and placenta seen within the anterior or posterior lip of the cervix, with a live embryo and/or yolk sac, and the presence of a rich vascular pattern around the sac were diagnostic for a cervical pregnancy.

The inclusion criteria

All patients who fulfilled the diagnostic criteria and consented to the double-balloon treatment after an evidence-based counseling were included in this study. The diagnosis, therapy, and follow-up of all patients were performed at the New York University Obstetrical and Gynecological Ultrasound Unit.

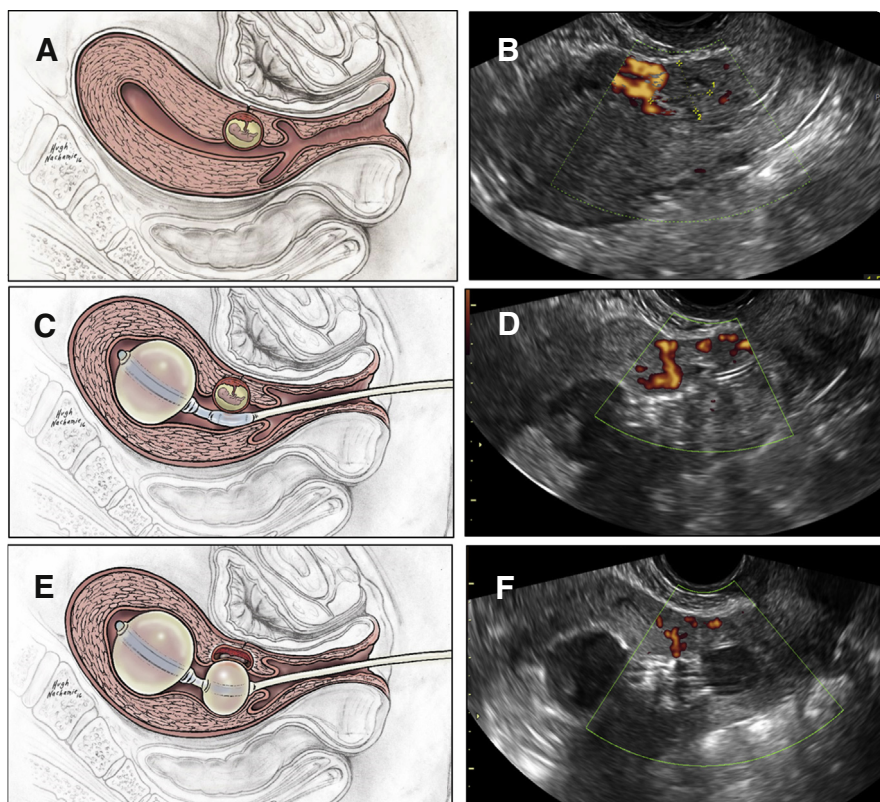
Inclusion criteria were gestational age between 6 and 8 weeks 6 days; demonstrable embryonic/fetal heart activity at the time of the ultrasound; a clearly stated desire for termination after evidence-based counseling describing the options for continuing or terminating the pregnancy; and signing an informed consent describing 2 treatment options of either local, intragastric methotrexate injection⁶ or the double-balloon technique described in the following text.

Description of the double-balloon–based treatment

Oral, nonsteroidal antiinflammatory pain medication was administered 2 hours before the procedure and continued as needed. Patients were prescribed a 5 day course of antibiotic treatment to be started on the day of treatment.

The patients were placed in lithotomy position. The vulva and vagina were prepped in a sterile fashion with betadine. An open-sided speculum was inserted, and the exposed cervix was cleaned with betadine. The size of the external cervical os was evaluated to fit the diameter of the catheter. If necessary, particularly in patients without prior vaginal delivery and/or no history of dilation and curettage, paracervical block (1% lidocaine) was administered followed by gently dilating the cervix to the size of Hegar number 7 to facilitate catheter placement. The uterus is imaged by a transabdominal ultrasound probe (Figure 2, A and B). The sterile gel-lubricated, double-balloon catheter was advanced into the uterine cavity under continuous, real time transabdominal ultrasound guidance using sponge forceps.

FIGURE 2
Placing a double-balloon catheter



The 3 steps of placing a double-balloon catheter using the artist's sketch juxtaposed to the corresponding color Doppler ultrasound images of an actual case. **A and B**, Before catheter placement, images of the cesarean scar pregnancy. **C and D**, Catheter in place and the upper anchor balloon was inflated. **E and F**, Both balloons are inflated.

Timor-Tritsch et al. A new treatment for cesarean scar and cervical pregnancies. *Am J Obstet Gynecol* 2016.

Under ultrasound guidance, the upper anchor balloon was inflated with 10 mL sterile saline to secure its position sonographically documented inside the uterine cavity (Figure 2, B and C). The speculum was removed and replaced by the transvaginal ultrasound probe. Under real time and continuous ultrasound observation, the lower-treatment balloon was positioned adjacent to the gestational sac. If needed, its position was readjusted inflating or deflating the anchoring upper balloon. The lower-treatment balloon was inflated by empirically adding saline until the gestational sac was flattened. The correct position of the balloon was sonographically documented (Figure 2, D and E).

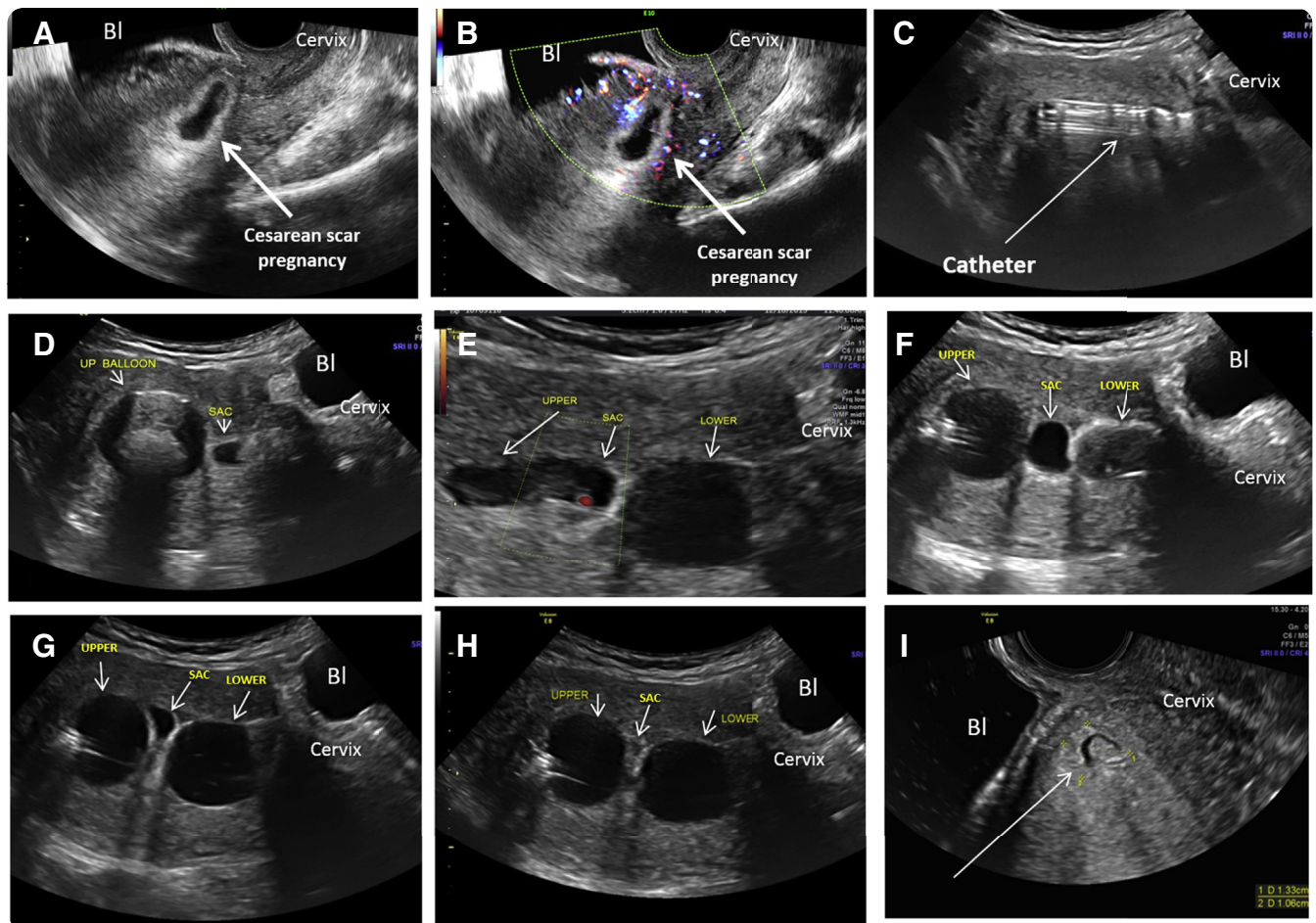
The process of catheter placement and inflation of the balloons as well as the removal of the catheter is demonstrated in the attached [video clip](#).

The area of the gestational sac and the lower balloon were observed by ultrasound, and if needed, saline was added to the balloons to prevent or stop any possible bleeding. Figures 3 and 4 present sequential and relevant ultrasound pictures obtained during treatments of a patient with cesarean scar pregnancy and a cervical pregnancy, respectively.

The patient was kept in the office under a nurse's observation for 1 hour after which the uterus was rescanned transabdominally. If no heart beats were seen and there was no sonographic or clinical evidence of bleeding, the patient

FIGURE 3

Catheter and balloon insertion, inflation, and removal in a cesarean scar pregnancy



The process of catheter and balloon insertion, inflation, and removal after 3 days in a patient with a cesarean scar pregnancy. **A**, Gray-scale image of the image of the cesarean scar pregnancy in the lower uterine segment. **B**, Power Doppler image of vascularity at the placental insertion of the cesarean scar pregnancy in the lower uterine segment. **C**, The arrow points to the double-balloon catheter in the uterine cavity before inflation. **D**, The upper balloon was inflated close to the gestational sac. **E**, Initial inflation of the lower balloon with the Doppler signal of the heart activity within the gestational sac between the 2 balloons before their final inflation. **F**, **G**, and **H** show the progressively collapsing gestational sac during additional, real-time, ultrasound-controlled inflation of the lower balloon. **I**, The remnants of the collapsed sac and its vascularity (*arrow*) after sequential deflation first of the lower, followed by that of the upper balloon, and extraction of the catheter.

Bl, bladder.

Timor-Tritsch et al. A new treatment for cesarean scar and cervical pregnancies. *Am J Obstet Gynecol* 2016.

was discharged with instructions to return 2-3 days later for evaluation and removal of the catheter. An emergency day and night cell phone number and a printed report describing the procedure was given to the patient, should an emergency room visit be necessary.

At the return visit, the lower balloon was first deflated under transvaginal ultrasound control. If no heart activity and no visible bleeding was seen, the patient was observed by the nurse for 1 hour and then rescanned. If no local

bleeding was noted, the upper balloon was deflated. If within an additional 30 minutes no change was detected, the catheter was removed and the patient discharged home with detailed instructions for scheduled repeat blood tests and ultrasound examinations.

Follow-up evaluation outcome

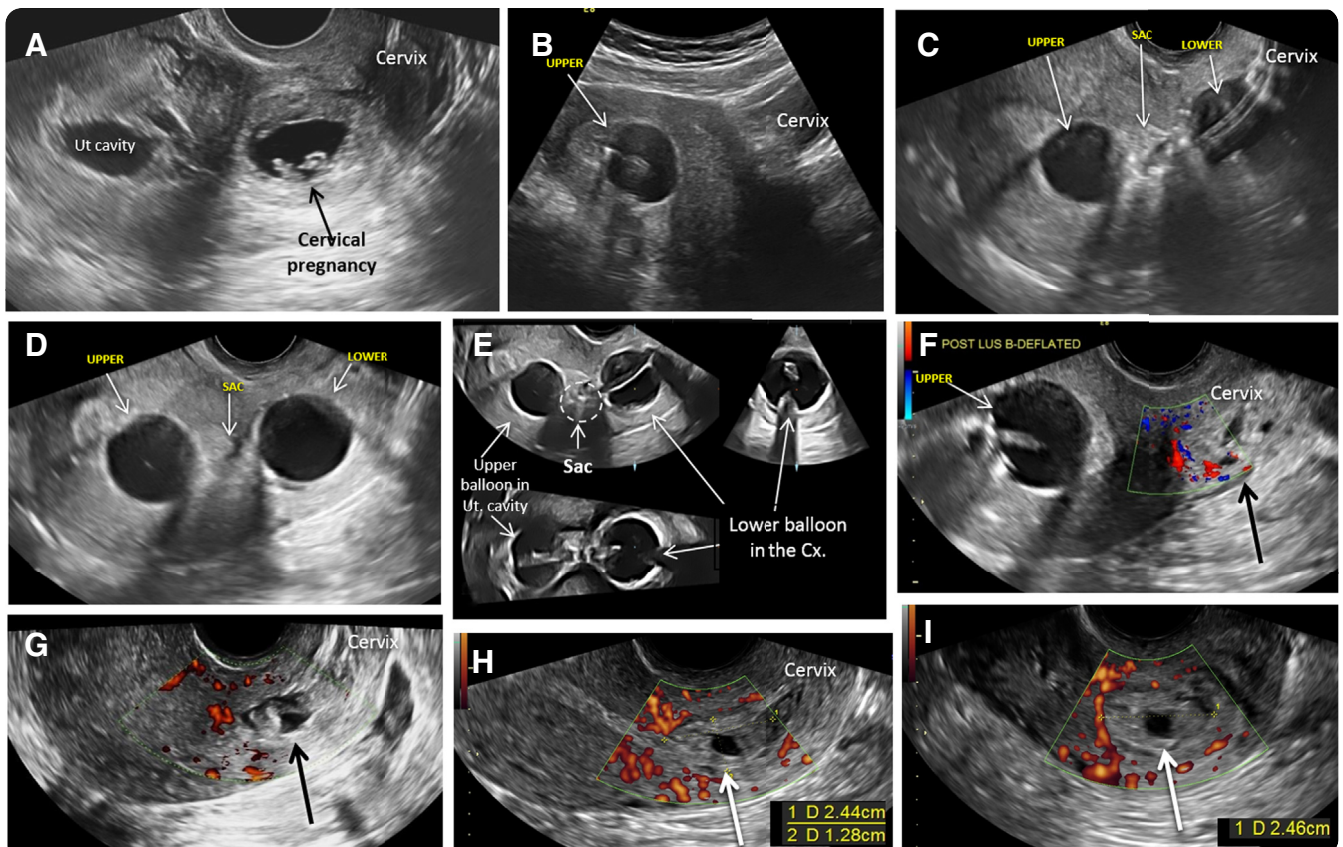
The patient's follow-up consisted of weekly ultrasound examinations until the area of the sac demonstrated diminished vascularity as judged

subjectively by the primary study investigators and until the gestational sac volume became smaller. Weekly serum human chorionic gonadotropin were obtained until nonpregnant values were noted. Birth control for 6 months was strongly suggested.

Statistical analysis

Statistical analyses were performed with IBM SPSS Statistics 22 (IBM Corp, Armonk, NY). Descriptive statistics (means and range) were calculated for:

FIGURE 4
Catheter and balloon insertion, inflation, and removal in a cervical pregnancy



The process of catheter and balloon insertion, inflation, and removal after 3 days in a patient with cervical pregnancy. **A**, Gray-scale image of the image of the cervical pregnancy in the lower uterine segment. **B**, The upper balloon inflated in the uterine cavity. **C**, Ultrasound image of both the upper and lower balloons inflated. Between them the sac is identified. **D**, Further inflation of the balloons compressed the gestational sac. **E**, Three-dimensional multiplanar ultrasound image of the balloons in place showing their spatial, interballoon relationships and the gestational sac between the 2 balloons. **F**, The lower balloon was deflated. The *arrow* points to the remnant of the sac. **G**, Gray-scale ultrasound image of the cervix (*arrow*) after both balloons were deflated and the catheter removed. **H** and **I** show the color Doppler image of the uterus with its vascularity and measurement of the residual sac (*arrows*) immediately after catheter removal.

Bl, bladder; Cx, cervix.

Timor-Tritsch et al. A new treatment for cesarean scar and cervical pregnancies. *Am J Obstet Gynecol* 2016.

gestational age, sac volume, and serum human chorionic gonadotropin at treatment, days the balloon was kept in place, and days until human chorionic gonadotropin returned to nonpregnant values. Serum human chorionic gonadotropin and gestational sac volumes were analyzed over time.

Results

During the study period, 12 patients were diagnosed with cesarean scar pregnancy and cervical pregnancy with live embryos at the time of the treatment. After counseling, 2 patients with

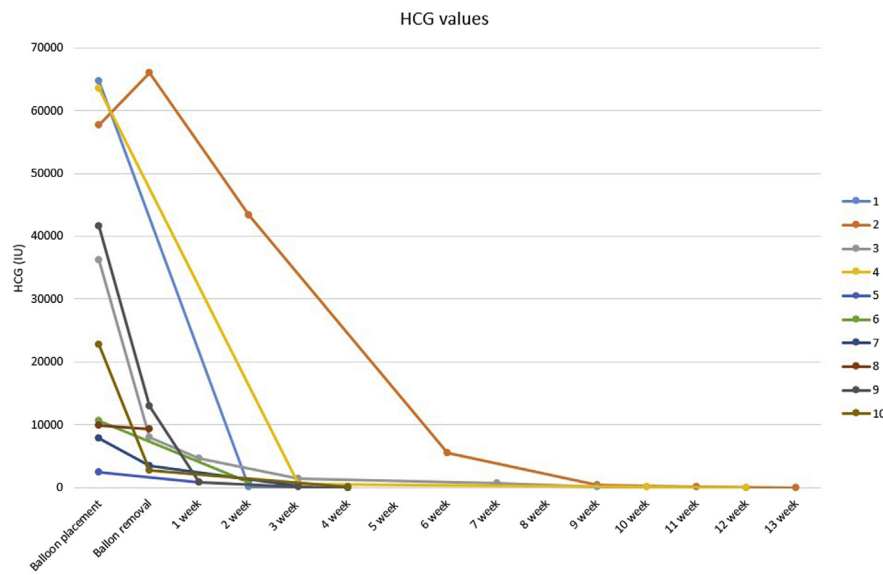
cesarean scar pregnancy preferred intragastric injection of methotrexate, and the double balloon was placed only for bleeding control. Thus, these 2 patients were excluded from statistical analysis. Ten patients (7 cesarean scar pregnancy and 3 cervical pregnancy) were treated by cervical double-balloon treatment and therefore were eligible for analysis.

Median gestational age was 6 6/7 weeks (range, between 6 3/7 and 7 4/7 weeks). Median gestational sac volume at treatment was 8.9 mL (range 2.5–25.8 mL). Median upper, anchor balloon was

inflated with 24.0 mL saline (range 10–30 mL), whereas that of the lower, treatment balloon was 15.0 mL (range 8–21 mL).

Balloons were kept in place for a median of 3 days (range, 1–5 days). Median serum human chorionic gonadotropin at the insertion of the balloons was 29,475 mIU/mL (range, 2488–64,700 mIU/mL). The median time for the human chorionic gonadotropin values to return to nonpregnant levels was 49 days (range, 28–97 days). In [Figures 5](#) and [6](#), the serum human chorionic gonadotropin and the gestational sac

FIGURE 5
The resolution of serum hCG over time of all 10 patients



HCG, human chorionic gonadotropin.

Timor-Tritsch et al. A new treatment for cesarean scar and cervical pregnancies. Am J Obstet Gynecol 2016.

volume are documented as a function of time.

Patients reported a minimal amount of spotting and bleeding of dark blood, mainly 1 or 2 days after treatment. They tolerated the placement of the balloons

adequately, reporting pain at inflation of the lower balloon that decreased during the hour observational period in the office. While catheters were in place, patients were followed up with daily phone calls to monitor their status. Two

patients presented to the emergency department for lower abdominal cramps after the catheter was in place for 2 days. The cause of the pain was the balloon passing and dilating the cervix. Once the balloons were expelled, the pain stopped. No excess bleeding was reported and no embryonic heart activity was documented. The patients were discharged home within hours.

Evaluation of the double-balloon treatment method

All patients reported low abdominal pressure at the inflation phase of the catheters. As expected, inflation of the lower balloon was associated with a degree of reported pain. After being aware of this pressure effect, patients were medicated with oral Ibuprofen (400-600 mg) 2 hours before the procedure and continued the medication as needed.

As hypothesized, the upper, anchor balloon kept the catheter in place for at least 1 day, providing adequate hemostasis.

The procedure achieved the set goals, proving our hypotheses: embryonic heart beats were successfully stopped as judged by the 1 or 2 hour ultrasound scan, and no significant bleeding occurred.

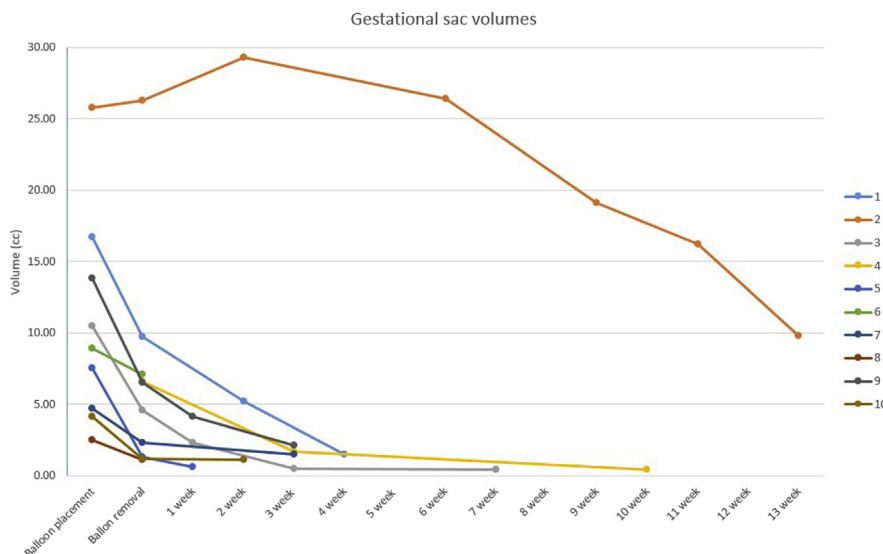
All patients were compliant and returned for their blood tests and ultrasound examinations as scheduled.

Patients reported a feeling of safety and reassurance with direct telephone communication and follow-up calls to evaluate their vaginal spotting, bleeding, or other concerns. We consider this as an important ingredient of patient compliance with the described, presently still unusual treatment procedure.

Comment
Evolution of evidence based patient counseling

Cesarean scar pregnancy is a dangerous clinical entity, regardless of the treatment chosen. The reason for this is its basic, underlying histology.⁷ It is now clear that cesarean scar pregnancy is one of the main precursors of morbidly adherent placenta.^{4,7,8} Before our understanding of the previously discuss text, the majority of the obstetrics and gynecology

FIGURE 6
The diminishing gestational sac sizes over time of all 10 patients



Timor-Tritsch et al. A new treatment for cesarean scar and cervical pregnancies. Am J Obstet Gynecol 2016.

community almost unequivocally suggested termination of cesarean scar pregnancies. Only a handful of articles reported the possibility of continuing a pregnancy implanted in the scar of a previous cesarean delivery, which resulted in several dozen live deliveries and patient counseling changed.^{4,9,10}

The approach of our group was no different. In the last several years, we counseled patients with cesarean scar pregnancy to make an informed choice between terminating or continuing their gestation based on the possibility of achieving the delivery of a live neonate with the real risk of hysterectomy for a morbidly adherent placenta. The challenges of continuing the pregnancy are described elsewhere.^{4,9,10}

If termination of the pregnancy is chosen, there is an excessive amount of available options published in the literature.³ Most treatments are slow to act, invasive, or carry significant complications.³ Our experience is that procrastination and the use of systemic methotrexate are 2 of the most frequently described interventions requiring more involved, secondary treatments.

It is true that a certain number of cesarean scar pregnancies, just as intra-uterine pregnancies, may terminate on their own. However, waiting for this to happen is not a practical or acceptable option. If effective at all, systemic administration of methotrexate, either as a single or even multiple doses, was shown to be effective only after several days.³

In both cases, waiting for the pregnancy to terminate allows the gestational sac and the embryo to grow along with its vascular supply. Reaching for a second-line treatment, the clinician is bound to encounter a larger sac with its significantly increased network of surrounding blood vessels. A backup procedure such as a dilation and curettage (the preferred treatment as reported by the published literature) may result in an unsuspected profuse bleeding that can be stopped only by major surgery, such as hysterectomy or uterine artery embolization.³ The reason for the bleeding is that the cervix, unlike the

uterine myometrium, does not contain sufficient muscular tissue to stop bleeding by constricting the bleeding vessels as in the case of curetting the uterine cavity.³

Rationale of using a double-balloon method in cesarean scar pregnancy and cervical pregnancy

Treating obstetrical hemorrhage by means of tamponing is well established. Packing the uterus with sterile gauze was one of the historical methods.^{11,12} Recently different types of inflatable balloons of various shapes were used to slow or stop bleeding by inflating them with saline, which exerted pressure on the blood vessels until full hemostasis is achieved. Examples are the Bakri balloon,^{13,14} the Rush balloon,^{15,16} and the double cervical ripening balloon inserting and inflating both balloons in the uterine cavity.¹⁷ Placing balloon catheters in cases of postabortal hemorrhage was also published.¹⁸ The adjunct use of balloon catheters were also part of the treatment of cervical pregnancies.¹⁹⁻²²

Combining our previous experience of using single-balloon tamponade in cesarean scar pregnancy and cervical pregnancy with the positive results of the obstetrical community in treating obstetrical hemorrhage using balloon tamponade gave rise of our hypothesis to achieve not only hemostasis but also to stop the heart activity at the same time. We were further encouraged by the latest publication by Dildy et al,²³ who successfully tested a specially designed and custom-manufactured double balloon catheter in 51 cases of obstetrical hemorrhage.

How long should the catheters be left in place?

The length of time we left the catheters in place was entirely empirical. In our previously published article treating 18 patients, the mean time was 3.6 days (range, 1–6 days⁵). Fylstra and Coffey²² used a single Foley balloon inflated in the cervix to prevent bleeding after local injection of cervical pregnancies, leaving the balloon in place for approximately 24 hours in anticipation of adequate hemostasis. Tsui

et al¹⁷ kept the balloons in place in 2 cases of obstetrical hemorrhage for 3 and 7 days, respectively, with the expected effect and without adverse complication. Dildy et al²³ left their newly tested double balloons to treat postpartum hemorrhage in place for a mean of 20.3 hours (range, 0.3–35 hours). Bakri balloons were kept in place for 22 ± 3 hours in 66 of 71 successful cases to stop postpartum hemorrhage and 3 ± 1 hours in 5 of the unsuccessful cases.²⁴

It is difficult to draw meaningful information from the experience of the previously mentioned authors as to the optimal length to leave balloons in place. It seems that the time to stop the heart activity is short and can be measured in hours. The main question is, what is the necessary time from the occlusion of potentially bleeding vessels to prevent bleeding after the catheter is removed?

The fact that the catheter caused low abdominal cramps in 2 patients, probably because of the balloons dilating the cervix, has dual implications. First, even the anchoring balloon was too small to prevent expulsion. Second, if patients signal severe pain, catheters have to be promptly deflated or removed. Further clinical trials have to be directed to find not only the adequate and minimum time to keep catheters in place but also to find the proper and lowest effective fluid volume in the balloons.

Profile of patients who would be best candidates for the treatment

These are patients with live cesarean scar pregnancy and/or cervical pregnancy between 6 and 8 weeks and a strong desire for future fertility or to preserve the uterus. Their previous vaginal delivery or previous cesarean delivery should have been performed at an advanced dilatation of the cervix or have had a previous dilation and curettage. The patients must be aware that in case of failure, subsequent treatment may call for other treatments such as uterine artery embolization and/or hysterectomy. The patient must agree to follow-up frequent blood tests and ultrasound examinations. An informed consent form must be signed containing the cited information.

Strength and weakness of the study

The strength of this study is that it is an office-based procedure and all patients had the desired positive outcomes with personalized, close follow-up by the authors. The relatively widely available expertise of placing cervical ripening double balloons in the labor and delivery room setting for labor induction may make this treatment more attractive and available to a larger number of practicing obstetricians-gynecologists than other treatments involving local intragestational injections and/or more involved surgical or radiological treatments.

The weakness of the study is the low number of patients treated. Therefore, possible rare complications may not be investigated in this study. However, no complications were experienced following the double-balloon treatment. The length of time for the catheter to be kept in place as well as the optimal inflation volumes has to be studied further.

Conclusion

We explored the feasibility and effectiveness of treating early 6-8 week cesarean scar pregnancy and cervical pregnancy by avoiding invasive treatment using a previously known cervical ripening double-balloon catheter. We evaluated its ability to stop the heart activity and at the same time to prevent possible local bleeding. Such catheters are frequently used for labor induction, and there is a wide familiarity by obstetricians. This therapeutic mode was found to be simple, safe, and effective with high patient acceptance. It may be considered in a selective number of patients. Further evaluation of this technique by treating a larger number of patients and additional centers or offices is necessary. ■

References

1. Larsen JV, Solomon MH. Pregnancy in a uterine scar sacculus—an unusual cause of

postabortal haemorrhage. A case report. *S Afr Med J* 1978;53:142-3.

2. Jurkovic D, Hillaby K, Woelfer B, Lawrence A, Salim R, Elson CJ. First-trimester diagnosis and management of pregnancies implanted into the lower uterine segment cesarean section scar. *Ultrasound Obstet Gynecol* 2003;21:220-7.

3. Timor-Tritsch IE, Monteagudo A. Unforeseen consequences of the increasing rate of cesarean deliveries: early placenta accreta and cesarean scar pregnancy. A review. *Am J Obstet Gynecol* 2012;207:14-29.

4. Timor-Tritsch IE, Monteagudo A, Cali G, et al. Cesarean scar pregnancy is a precursor of morbidly adherent placenta. *Ultrasound Obstet Gynecol* 2014;44:346-53.

5. Timor-Tritsch IE, Cali G, Monteagudo A, Khatib N, Berg RE, Forlani F, Avizova E. Foley balloon catheter to prevent or manage bleeding during treatment for cervical and cesarean scar pregnancy. *Ultrasound Obstet Gynecol* 2015;46:118-23.

6. Timor-Tritsch IE, Monteagudo A, Santos R, Tsybal T, Pineda G, Arslan AA. The diagnosis, treatment, and follow-up of cesarean scar pregnancy. *Am J Obstet Gynecol* 2012;207:44.e1-13.

7. Timor-Tritsch IE, Monteagudo A, Cali G, et al. Cesarean scar pregnancy and early placenta accreta share common histology. *Ultrasound Obstet Gynecol* 2014;43:383-95.

8. Ben Nagi J, Ofili-Yebovi D, Marsh M, Jurkovic D. First-trimester cesarean scar pregnancy evolving into placenta previa/accreta at term. *J Ultrasound Med* 2005;24:1569-73.

9. Ballas J, Pretorius D, Hull AD, Resnik R, Ramos GA. Identifying sonographic markers for placenta accreta in the first trimester. *J Ultrasound Med* 2012;31:1835-41.

10. Zosmer N, Fuller J, Shaikh H, Johns J, Ross JA. Natural history of early first-trimester pregnancies implanted in cesarean scars. *Ultrasound Obstet Gynecol* 2015;46:367-75.

11. Drucker M, Wallach RC. Uterine packing: a reappraisal. *Mt Sinai J Med* 1979;46:191-4.

12. Schmid BC, Reznicek GA, Rolf N, Saade G, Gebauer G, Maul H. Uterine packing with chitosan-covered gauze for control of postpartum hemorrhage. *Am J Obstet Gynecol* 2013;209:225.e1-5.

13. Bakri YN. Uterine tamponade-drain for hemorrhage secondary to placenta previa-accreta. *Int J Gynaecol Obstet* 1992;37:302-3.

14. Bakri YN, Amri A, Abdul Jabbar F. Tamponade-balloon for obstetrical bleeding. *Int J Gynaecol Obstet* 2001;74:139-42.

15. Johanson R, Kumar M, Obhrai M, Young P. Management of massive postpartum

haemorrhage: use of a hydrostatic balloon catheter to avoid laparotomy. *BJOG* 2001;108:420-2.

16. Keriakos R, Mukhopadhyay A. The use of the Rusch balloon for management of severe postpartum haemorrhage. *J Obstet Gynaecol* 2006;26:335-8.

17. Tsui KH, Lin LT, Yu KJ, et al. Double-balloon cervical ripening catheter works well as an intrauterine balloon tamponade in post-abortion massive hemorrhage. *Taiwan J Obstet Gynecol* 2012;51:426-9.

18. Olamijulo JA, Doufekas K. Intrauterine balloon tamponade for uncontrollable bleeding during first trimester surgical termination of pregnancy. *J Obstet Gynaecol* 2007;27:440-1.

19. Bakour SH, Thompson PK, Khan KS. Successful conservative management of cervical ectopic pregnancy with combination of methotrexate, mifepristone, surgical evacuation and tamponade using a double balloon three-way catheter. *J Obstet Gynaecol* 2005;25:616-8.

20. De La Vega GA, Avery C, Nemiroff R, Marchiano D. Treatment of early cervical pregnancy with cerclage, carboprost, curettage, and balloon tamponade. *Obstet Gynecol* 2007;109:505-7.

21. Fylstra DL. Cervical pregnancy: 13 cases treated with suction curettage and balloon tamponade. *Am J Obstet Gynecol* 2014;210:581.e1-5.

22. Fylstra DL, Coffey MD. Treatment of cervical pregnancy with cerclage, curettage and balloon tamponade. A report of three cases. *J Reprod Med* 2001;46:71-4.

23. Dildy GA, Belfort MA, Adair CD, et al. Initial experience with a dual-balloon catheter for the management of postpartum hemorrhage. *Am J Obstet Gynecol* 2014;210:136.e1-6.

24. Gao Y, Wang Z, Zhang J, et al. [Efficacy and safety of intrauterine Bakri balloon tamponade in the treatment of postpartum hemorrhage: a multicenter analysis of 109 cases]. *Zhonghua Fu Chan Ke Za Zhi* 2014;49:670-5.

Author and article information

From the Department of Obstetrics and Gynecology, New York University School of Medicine (Drs Timor-Tritsch, Monteagudo, Bennett, Foley, and Kaelin Agten and Ms Ramos), and Maternal-Fetal Medicine Associates, Carnegie Hill Imaging for Women (Dr Monteagudo), New York, NY.

Received Feb. 17, 2016; revised March 2, 2016; accepted March 7, 2016.

The authors report no disclosures or conflicts of interest.

Corresponding author: Ilan E. Timor-Tritsch, MD. ilan.timor@nyumc.org