



A New Simple Technique for 3-Dimensional Sonographic Assessment of the Pelvic Floor Muscles

Aly Youssef, MD, Elisa Montaguti, MD, Olimpia Sanlorenzo, MD, Luisa Cariello, MD, Elsayed Elbadawy Awad, MD, Giuseppina Pacella, MD, Tullio Ghi, MD, PhD, Gianluigi Pilu, MD, Nicola Rizzo, MD

 Article includes CME test

 Supplemental material online at www.jultrasoundmed.org

 Videos online at www.jultrasoundmed.org

Received March 28, 2014, from the Department of Obstetrics and Gynecology, Sant'Orsola Malpighi University Hospital, University of Bologna, Bologna, Italy (A.Y., E.M., O.S., L.C., G.P., T.G., G.P., N.R.); and Department of Obstetrics and Gynecology, El-Shatby Maternity Hospital, Alexandria University, Alexandria, Egypt (E.E.A.). Revision requested April 14, 2014. Revised manuscript accepted for publication April 16, 2014.

Address correspondence to Aly Youssef, MD, Department of Obstetrics and Gynecology, Sant'Orsola-Malpighi University Hospital, University of Bologna, Via Massarenti 13, 40138 Bologna, Italy.

E-mail: aly.youssef78@gmail.com

Abbreviations

CI, confidence interval; ICC, intraclass correlation coefficient; LOA, limits of agreement; 3D, 3-dimensional; VCI, Volume Contrast Imaging

doi:10.7863/ultra.34.1.65

Objectives—The purpose of this study was to assess the reproducibility of a new technique for 3-dimensional (3D) pelvic floor sonography: OmniView combined with Volume Contrast Imaging (VCI; GE Healthcare, Kretz Ultrasound, Zipf, Austria) for pelvic hiatal area measurement. In addition, we aimed to study the intermethod agreement between the new technique and the standard 3D rendering method.

Methods—We acquired a static 3D sonographic transperineal volume from 124 nulliparous asymptomatic women and 118 women with symptoms of pelvic floor dysfunction. Each 3D data set was analyzed by the OmniView-VCI technique to measure the pelvic hiatal area twice by one operator and once by another to assess intraobserver and interobserver reproducibility. The first operator later measured the hiatal area using the 3D rendering method to evaluate intermethod agreement. Reproducibility and intermethod agreement were studied by the intraclass correlation coefficient and Bland-Altman method.

Results—Hiatal area measurements by the OmniView-VCI technique showed high intraobserver and interobserver reproducibility in both asymptomatic and symptomatic women. In addition, high agreement was shown between the new technique and 3D rendering in both groups. No systematic differences were noted in any of the reliability studies performed. The new technique took slightly less time to calculate the hiatal area than the standard rendering method in both asymptomatic and symptomatic women.

Conclusions—OmniView-VCI is a reliable method for pelvic hiatal area measurement. Further studies are needed to assess its reliability under contraction and the Valsalva maneuver and to evaluate its usefulness and reproducibility for diagnosis of levator ani lesions.

Key Words—gynecologic ultrasound; levator ani muscle; OmniView; pelvic floor; 3-dimensional sonography; Volume Contrast Imaging

The levator ani muscle plays an important role in supporting pelvic organs. Women with obstetric levator ani muscle avulsion have a risk of developing major pelvic organ prolapse, which is double compared with those with no levator ani muscle injury.^{1,2} Furthermore, the dimensions of the pelvic hiatus are strongly associated with female pelvic organ prolapse, and there is a well-established correlation between the size of the levator hiatus and the risk pelvic organ descent.³

Although levator ani muscle injury may be detected both by clinical examination and by sonography, palpatory detection of major levator ani muscle trauma is less repeatable than sonographic assessment.⁴ Evaluation of the levator ani muscle and hiatal area measurements are reliably achieved by 3-dimensional (3D) sonog-

raphy and have shown a good correlation with pelvic floor dysfunction.^{2,5-7} The planes displayed by the 3D technique are, however, Euclidean and flat, as opposed to the anatomic shape of the pelvic floor, which is non-Euclidean (warped).⁸ Applying the simple multiplanar technique for such an aim can provide insufficient anatomic information and can lead to an overestimation of the hiatal area.⁹ To avoid the possibility of a measurement error, the 3D rendering method, which reconstructs various layers of the pelvic floor, has been suggested.^{8,10,11} Another possibility to avoid measurement error in this plane is to analyze data included in various planes by Volume Contrast Imaging (VCI; GE Healthcare, Milwaukee, WI). The latter technique improves contrast by eliminating noise and enhancing anatomic structures included in the whole thickness of the region analyzed. Nevertheless, it has been noted that VCI is time-consuming.⁸ By adding a new technology (OmniView; GE Healthcare, Kretz Ultrasound, Zipf, Austria), 3D reconstruction using the VCI technique can be performed easily and rapidly through any selected plane on 3D volumes by depicting a simple line, thus avoiding the necessity of volume rotation on the Z-plane. To our knowledge, the effectiveness of the combination of these techniques (OmniView-VCI) for pelvic floor assessment has never been investigated.

The aim of this study was to assess the reproducibility of the OmniView-VCI technique for measurement of the pelvic hiatal area in both nulliparous asymptomatic women and a group of women with symptoms of pelvic floor dysfunction. In addition, we aimed to study the intermethod agreement between the new technique and the standard previously suggested 3D rendering method, which is considered the reference standard for this assessment. Last, we aimed to evaluate the time needed for such an evaluation and to compare it with the rendering technique.

Materials and Methods

The study protocol was approved by the local Ethical Committee of our university hospital, and a consent form signed at recruitment was obtained from each eligible patient. The protocol conformed to the ethical guidelines of the Declaration of Helsinki.

From January to December 2012, 129 nulliparous asymptomatic healthy volunteers and 127 women with symptoms suggestive of pelvic floor dysfunction were recruited for the study. In the symptomatic group, 61 women (48.0%) were referred for urinary incontinence, and 19 (15%) had fecal incontinence, whereas 46 (36.2%) were referred for pelvic organ prolapse, and 15 (11.8%)

had dyspareunia. All women underwent an interview and a transperineal sonographic examination.

Sonographic Volume Acquisition

A static 3D volume was acquired from all participants as previously described¹¹ by 1 of 3 operators with variable experience in 3D sonography (A.Y., E.M., and T.G.). A Voluson E8 system (GE Healthcare) with an RAB 8–4-MHz volume transducer, covered by a sterile glove was used for all acquisitions. The 3D volume was acquired at rest in the modified lithotomy position and with an empty bladder, using high quality and a wide acquisition angle (70°–85°). The convex volumetric ultrasound transducer was positioned translabially in the midsagittal plane (Figure 1). This plane included the entire levator hiatus with the symphysis pubis, urethra, paravaginal tissues, vagina, anorectum, and puborectalis loop from the pelvic sidewall in the area of the arcus tendineus of the levator ani to the posterior aspect of the anorectal junction.

Volume Analysis

All volumes were saved on the ultrasound machine and later transferred anonymously to a personal computer equipped with dedicated software (4D View 9.0; GE Healthcare) for offline analysis. After the study, the pelvic hiatal area was measured by the OmniView-VCI technique (Figure 2) twice by an operator with more than 5 years of experience in 3D sonography (operator 1, A.Y.), and once by another operator with less than 1 year of experience in 3D sonography (operator 2, E.M.) to investigate the intraobserver and interobserver reproducibility of the new technique. The pelvic hiatal area was also measured by the previously described rendering method⁸ once by operator 1 to calculate the intermethod agreement (first measurement by operator 1 versus rendering method). The times needed for the hiatal area measurement by OmniView-VCI (first measurement by operator 1) and by 3D rendering were recorded. The time count was started when each volume was successfully loaded and ready to be analyzed. This time included plane adjustment and hiatal area measurement. To minimize bias, an interval of at least 1 week between any two analyses of the same volume was established. If a volume quality was considered poor, thus hindering hiatal area measurement, by either or both of the operators, the volume was excluded from the analysis.

OmniView-VCI Technique

The VCI technique superimposes and includes different layers of tissue in image construction, reducing and eliminating speckles and noise pixels that are generated at random,

whereas anatomical structures are enhanced, leading to improved contrast and a smoother image (Figure 2). On the other hand, the OmniView technique allows slicing of a volume in the multiplanar mode along any required plane by simple depiction of a line along the selected plane. Accordingly, the combination of the OmniView and VCI techniques allows the analysis of 3D volumes along any plane, including a slice with a designated thickness, producing high-contrast, smooth images (Figure 2). In our study, this method was applied to the previously described plane minimal hiatal dimensions.¹¹⁻¹³ The latter plane runs from the posterior margin of the symphysis pubis to the anterior margin of the puborectalis muscle, where it defines the anorectal angle.⁵ The 3D volume was opened and checked for proper alignment on the various planes. The

OmniView-VCI application was then activated. The plane of minimal hiatal dimensions was obtained by drawing a line on the midsagittal plane running from the posterior margin of the symphysis pubis to the anterior margin of the puborectalis muscle at the anorectal angle including a thickness of 10 to 20 mm, avoiding the need for rotation of the Z-plane (Video 1 and Figure 2).

Rendering Technique

For all volumes, we measured the hiatal area using the rendering technique as previously described.^{11,12} In brief, the 3D volume was opened and checked for proper alignment on the various planes. Rotation on plane A was performed to align the posterior margin of the symphysis pubis and the anterior margin of the puborectalis muscle, where it

Figure 1. Multiplanar display of a 3D volume acquired translabially in the midsagittal plane. The multiplanar mode shows the 3 perpendicular planes: midsagittal (A), coronal (B), and axial (C). The main structures identified on the acquisition plane (A) are from left to right: symphysis pubis (SP), urethra (U), vagina (V), rectum (R), and puborectalis muscle (PR) passing behind the rectum.

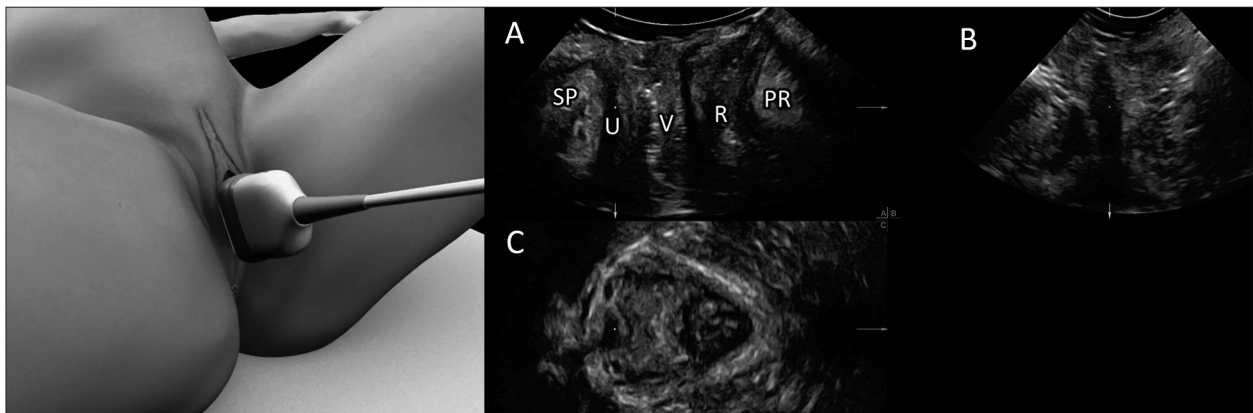
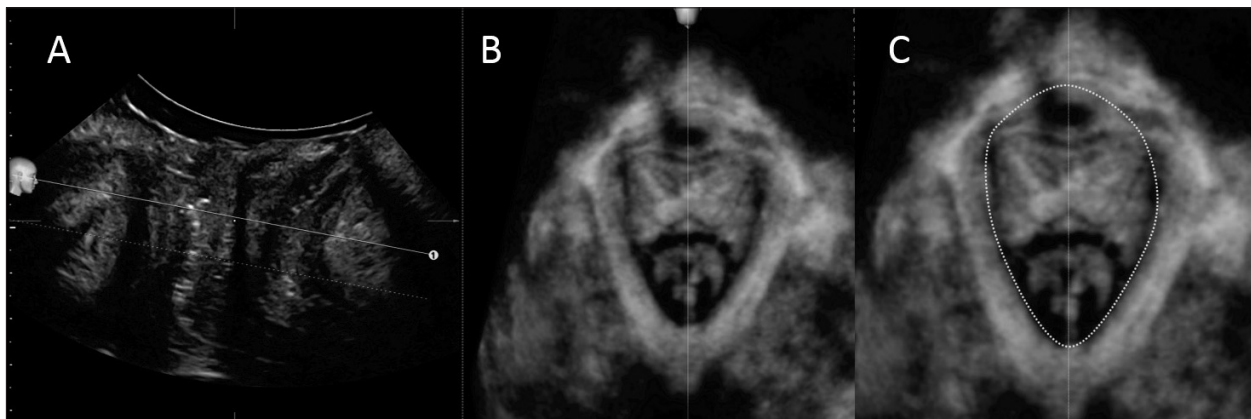


Figure 2. OmniView-VCI technique. The line from OmniView-VCI is drawn along the plane of least pelvic hiatal dimensions between the posterior margin of the symphysis pubis and the anterior margin of the puborectalis muscle, where it defines the anorectal angle, including a thickness of 10 to 20 mm (A). The plane of hiatal dimensions is automatically displayed on the right hand side (B). The trace method is then used to measure the pelvic hiatal area (C).



defines the anorectal angle on the same horizontal level. The 3D rendering application was then activated. Rendered volumes were set at a thickness of 1.5 to 2.5 cm, with the plane of minimal dimensions included in the region of interest, which delineated the rendered volume, with the rendering direction set from caudal to cranial. Thickness was adjusted to optimize visualization of insertion of the puborectalis muscle, which depends on a number of factors, including the patient's muscle mass, image quality, and contraction quality. The standard rendering setting was surface/minimum 80/20, with transparency set at 50. Figure 3 illustrates the same 3D volume in the same woman, analyzed by the OmniView-VCI (Figure 3A) and the 3D rendering (Figure 3B) techniques.

Statistics

Continuous data, including hiatal area values, are given as mean \pm standard deviation. An independent-samples Student *t* test was performed to analyze differences between asymptomatic and symptomatic women. Agreement between the examiners and between the measurements made by the first examiner, as well as the agreement between OmniView-VCI and 3D rendering, was expressed as intraclass correlation coefficients (ICCs) for single measurements and 95% confidence intervals (CIs) for the ICCs.¹⁴ The systematic differences were also computed by a paired Student *t* test.

For repeatability, to assess the systematic bias between intraobserver versus interobserver and OmniView-VCI versus 3D rendering measurements, differences between values were plotted against means of the measurements as described by Bland and Altman,¹⁵ and the limits of agreement (LOA) were evaluated together with their 95% CIs.¹⁵ The repeatability coefficients were also computed.¹⁶

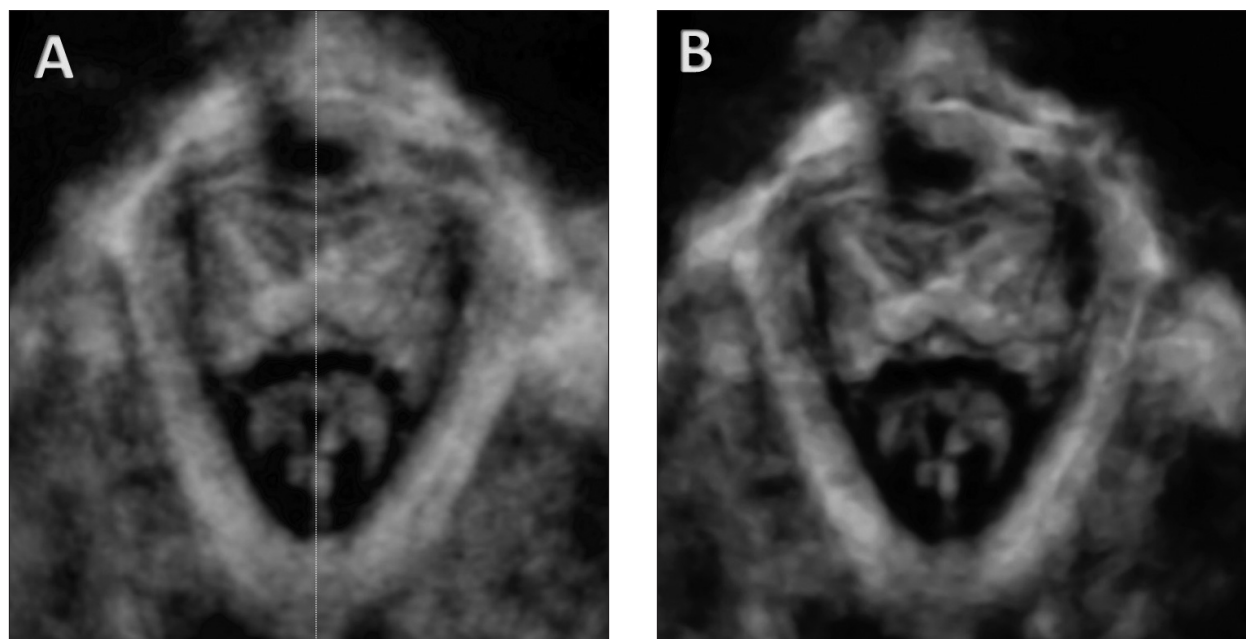
The statistical analyses were performed with SPSS version 13.0 software for Windows (IBM Corporation, Armonk, NY). Two-tailed *P* < .05 was considered significant.

Results

Among the volumes acquired, 5 in the asymptomatic group and 9 in the symptomatic group were considered of inadequate quality for levator ani assessment by both operators. The final analysis was thus performed on 124 volumes in the asymptomatic group and 118 in the symptomatic group. The patients' characteristics and hiatal areas in the groups are displayed in Table 1.

The results of the analyses of agreement in asymptomatic and symptomatic women are shown in Tables 2 and 3, respectively. As shown in the tables, hiatal area measurement by the OmniView-VCI technique had high intraobserver and interobserver reproducibility in both groups. In addition, high agreement was shown between OmniView-VCI and the previously suggested standard 3D

Figure 3. Comparison of images obtained by the OmniView-VCI technique (A) and the 3D rendering technique (B).



rendering in both asymptomatic and symptomatic women. Furthermore, no systematic differences were shown in any of the reliability studies performed in both groups. The individual patient data for hiatal areas in both groups are available online (supplemental Table 4).

Table 1. Patient Characteristics and Hiatal Areas in Nulliparous Asymptomatic and Symptomatic Women

Characteristic	Nulliparous Asymptomatic Women (n = 124)	Symptomatic Women (n = 118)
Age, y	23.4 ± 2.7	45.9 ± 12.8
Parity	0.0 ± 0.0	1.5 ± 0.8
Body mass index, kg/m ²	21.0 ± 3.0	25.9 ± 4.1
Hiatal area, cm ²		
OmniView-VCI	13.18 ± 2.30	15.85 ± 4.49
Rendering	13.12 ± 2.35	15.77 ± 4.58

Data are presented as mean ± SD.

Bland-Altman plots of the intraobserver, interobserver, and intermethod agreement in asymptomatic and symptomatic women are shown in Figures 4 and 5, respectively. Moreover, the time needed for hiatal area measurement by OmniView-VCI was significantly shorter than that for the standard rendering method in both the asymptomatic group (41.5 ± 9.0 versus 71.7 ± 16.8 seconds; *P* < .001) and the symptomatic group (44.5 ± 7.2 versus 72.7 ± 13.3 seconds; *P* < .001).

Discussion

In this study, we provided original data on a new simple technique for pelvic floor muscle evaluation: OmniView-VCI. Using this technique, we were able to measure the pelvic hiatal area rapidly and reliably at rest in both healthy nulliparous women and women with symptoms of pelvic dysfunction. We demonstrated that OmniView-VCI has

Table 2. Intraobserver and Interobserver Reproducibility and Intermethod Reliability for Pelvic Hiatal Area Measurement in Nulliparous Asymptomatic Women

Parameter	Intraobserver	Interobserver	Intermethod (Rendering vs VCI)
Mean difference, cm ²	-0.01 (-0.17 to 0.15)	0.03 (-1.47 to 0.76)	0.09 (-2.47 to 3.76)
Range of differences, cm ²	-3.05 to 2.99	-3.61 to 3.04	-2.47 to 3.76
Systematic difference, <i>P</i> ^a	.907	.680	.264
ICC	0.926 ^b (0.896 to 0.947)	0.930 ^b (0.902 to 0.950)	0.917 ^b (0.883 to 0.941)
95% LOA, cm ²			
Upper	1.75 (1.48 to 2.03)	1.69 (1.43 to 1.95)	1.94 (1.65 to 2.23)
Lower	-1.77 (-2.05 to -1.50)	-1.63 (-1.89 to -1.37)	-1.75 (-2.05 to -1.46)
Repeatability coefficient, cm ²	±1.76	±1.66	±1.85

Data in parentheses are 95% CIs.

^aStudent *t* test.

^b*P* < .001 versus 0.

Table 3. Intraobserver and Interobserver Reproducibility and Intermethod Reliability for Pelvic Hiatal Area Measurement in Symptomatic Women

Parameter	Intraobserver	Interobserver	Intermethod (Rendering vs VCI)
Mean difference, cm ²	0.14 (-0.01 to 0.29)	-0.60 (-0.95 to -0.24)	0.02 (-1.84 to 1.88)
Range of differences, cm ²	-1.85 to 2.04	-6.78 to 5.93	-2.19 to 2.43
Systematic difference, <i>P</i> ^a	.821	.334	.980
ICC	0.965 ^b (0.714 to 0.988)	0.908 ^b (0.862 to 0.938)	0.903 ^b (0.769 to 0.979)
95% LOA, cm ²			
Upper	1.76 (1.50 to 2.02)	3.25 (2.63 to 3.87)	2.04 (-1.22 to 5.31)
Lower	-1.47 (-1.73 to -1.22)	-4.45 (-5.07 to -3.83)	-2.00 (-5.26 to 1.27)
Repeatability coefficient, cm ²	±1.6	±3.8	±2.0

Data in parentheses are 95% CIs.

^aStudent *t* test.

^b*P* < .001 versus 0.

Figure 4. Bland-Altman plots of the first hiatal area measurement obtained in asymptomatic women by operator 1 using the OmniView-VCI technique versus the second measurement by operator 1 (A; intraobserver; correlation between average values and differences, $r = -0.012$; $P = .896$), the measurement by operator 2 (B; interobserver; $r = 0.010$; $P = .916$), and the measurement by the rendering method (C; $r = -0.092$; $P = .310$). Solid lines represent mean differences, and dashed lines represent 95% LOA (ie, mean difference ± 1.96 SD).

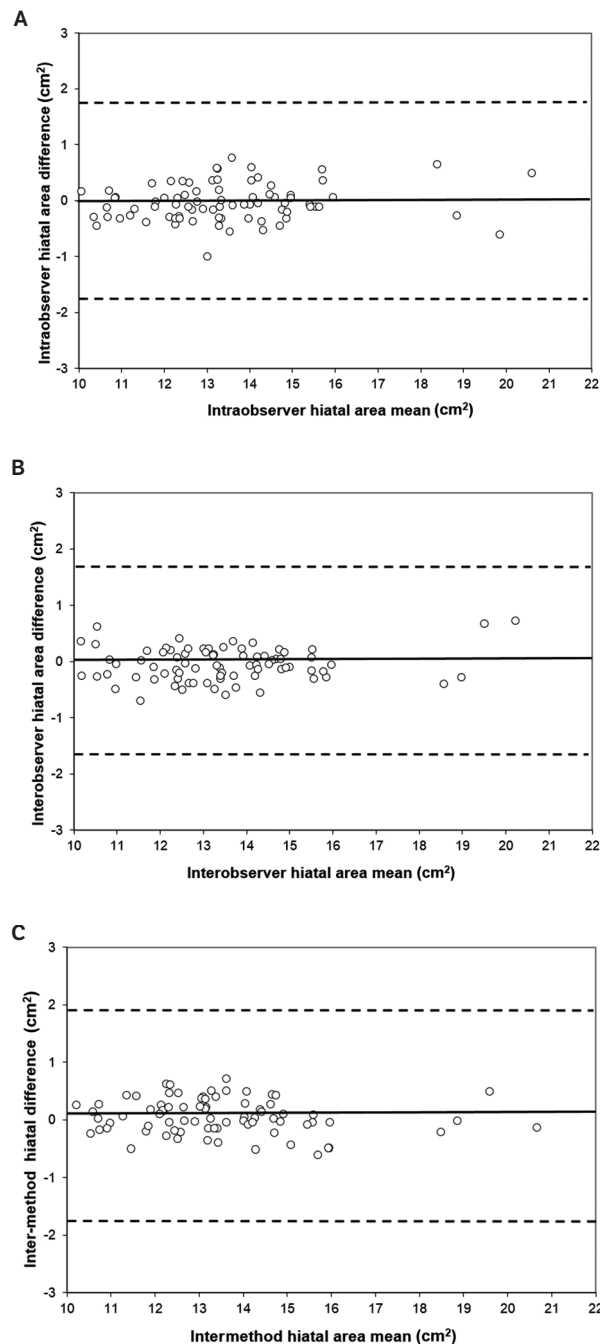
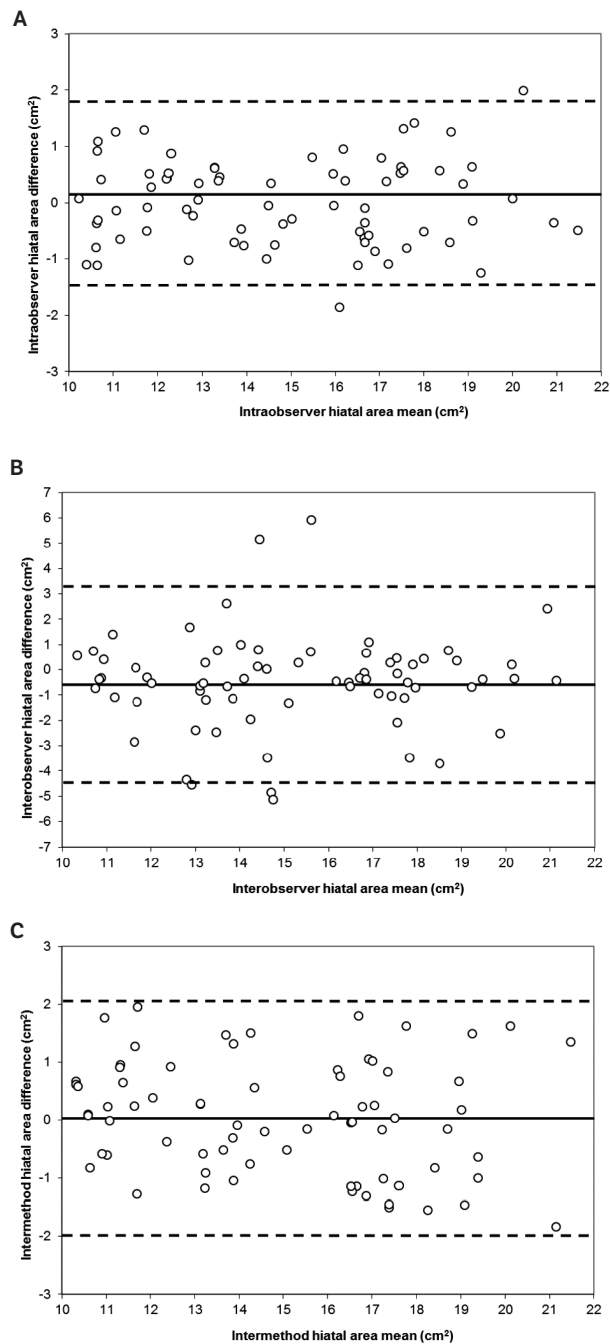


Figure 5. Bland-Altman plots of the first hiatal area measurement obtained in women with symptoms of pelvic floor dysfunction by operator 1 using the OmniView-VCI technique versus the second measurement by operator 1 (A; intraobserver; correlation between average values and differences, $r = 0.01$; $P = .983$), the measurement by operator 2 (B; interobserver; $r = 0.018$; $P = .923$), and the measurement by the rendering method (C; $r = -0.034$; $P = .951$). Solid lines represent mean differences, and dashed lines represent 95% LOA (ie, mean difference ± 1.96 SD).



high intraobserver and interobserver reproducibility, in addition to high agreement with the previously suggested and studied 3D rendering technique.^{8,10,12} In addition, we confirmed the relationship between the pelvic hiatal area and symptoms of pelvic floor dysfunction in our population.

By distending the pelvic hiatus, vaginal childbirth may lead to levator ani muscle injury in up to 30% of deliveries.¹⁷ This injury may take the form of avulsion (detachment of the puborectalis muscle from its insertion) or a permanent overdistension of the pelvic hiatus.^{18,19} Both levator ani muscle avulsion and overdistension of the pelvic hiatus are strongly associated with pelvic organ prolapse.²⁰ Unfortunately, almost all levator ani muscle injuries pass unnoticed on immediate postpartum evaluations.^{4,21}

An increasingly used method for levator ani muscle assessment is 3-/4-dimensional translabial sonography, particularly using rendered volumes, with the region of interest placed at the level of the minimal hiatal dimensions.¹¹ The use of the VCI technique has been previously suggested but was thought to be time-consuming.⁸ However, to our knowledge, the use of VCI for pelvic floor assessment has never been adequately investigated previously. By adding the possibility of reconstructing any 3D plane by OmniView without the need to adjust the region of interest (Video 1 and Figure 2), we were able to rapidly measure the pelvic hiatal area with high intraobserver and interobserver reproducibility. In addition, our measurements correlated highly with those performed by the widely used rendering method.¹¹ The main advantage of using the OmniView-VCI technique is that it permits the 3D reconstruction of a slice thickness on the plane of minimal hiatal dimensions without the need to rotate on the Z-plane. This reconstruction was obtained by simply depicting a line on the sagittal plane between the symphysis pubis and the anterior margin of the puborectalis muscle, where it defines the anorectal angle (Figure 2). It is worth noting that, although the second operator had less than 1 year of experience in 3D sonography, the hiatal area measurements showed high agreement with those produced by the experienced operator in both symptomatic and asymptomatic women. This finding is not surprising, considering the simple and standardized approach that we applied.

Our study had some weaknesses. First, we evaluated the feasibility and reproducibility of OmniView-VCI only at rest. A key assessment of the pelvic floor is the dynamic one. Although this assessment was not the aim of this study, we think that the simplicity and the speed with which the desired reconstructed axial plane is obtained may be useful in dynamic as well as static evaluations of the levator ani

muscle. The effectiveness of levator ani assessment by OmniView-VCI under pelvic floor muscle contractions and the Valsalva maneuver and its accuracy for diagnosis of levator ani muscle injury need to be assessed before recommending its routine use. Another limitation was the heterogeneity of the symptomatic group. However, as the main aim of our study was not a comparison or evaluation of each single dysfunction but rather the reproducibility of the new technique in different populations, we do not think that this factor should be considered a weakness in our study.

In conclusion, the OmniView-VCI technique is a rapid and reproducible method for pelvic hiatal area measurement in both nulliparous asymptomatic women and women with symptoms of pelvic floor dysfunction at rest. Further studies investigating its usefulness and reproducibility for diagnosis of levator ani lesions, as well as the reliability of hiatal area assessment under contraction and the Valsalva maneuver, are warranted.

References

1. Dietz HP, Simpson JM. Levator trauma is associated with pelvic organ prolapse. *BJOG* 2008; 115:979–984.
2. Schwertner-Tiepelmann N, Thakar R, Sultan AH, Tunn R. Obstetric levator ani muscle injuries: current status. *Ultrasound Obstet Gynecol* 2012; 39:372–383.
3. Dietz HP, Shek C, De Leon J, Steensma AB. Ballooning of the levator hiatus. *Ultrasound Obstet Gynecol* 2008; 31:676–680.
4. Dietz HP, Shek C. Validity and reproducibility of the digital detection of levator trauma. *Int Urogynecol J Pelvic Floor Dysfunct* 2008; 19:1097–1101.
5. Dietz HP, Shek C, Clarke B. Biometry of the pubovisceral muscle and levator hiatus by three-dimensional pelvic floor ultrasound. *Ultrasound Obstet Gynecol* 2005; 25:580–585.
6. Falkert A, Willmann A, Endress E, Meint P, Seelbach-Gobel B. Three-dimensional ultrasound of pelvic floor: is there a correlation with delivery mode and persisting pelvic floor disorders 18–24 months after first delivery? *Ultrasound Obstet Gynecol* 2013; 41:204–209.
7. Falkert A, Endress E, Weigl M, Seelbach-Gobel B. Three-dimensional ultrasound of the pelvic floor 2 days after first delivery: influence of constitutional and obstetric factors. *Ultrasound Obstet Gynecol* 2010; 35:583–588.
8. Dietz HP, Wong V, Shek KL. A simplified method for determining hiatal biometry. *Aust NZ J Obstet Gynaecol* 2011; 51:540–543.
9. Kruger JA, Heap SW, Murphy BA, Dietz HP. How best to measure the levator hiatus: evidence for the non-Euclidean nature of the “plane of minimal dimensions.” *Ultrasound Obstet Gynecol* 2010; 36:755–758.
10. Dietz HP. Pelvic floor ultrasound: a review. *Am J Obstet Gynecol* 2010; 202:321–334.
11. Dietz HP. Ultrasound imaging of the pelvic floor, part II: three-dimensional or volume imaging. *Ultrasound Obstet Gynecol* 2004; 23:615–625.

12. Dietz HP, Moegni F, Shek KL. Diagnosis of levator avulsion injury: a comparison of three methods. *Ultrasound Obstet Gynecol* 2012; 40:693–698.
13. Dietz HP, Shek KL. Tomographic ultrasound imaging of the pelvic floor: which levels matter most? *Ultrasound Obstet Gynecol* 2009; 33:698–703.
14. Rankin G, Stokes M. Reliability of assessment tools in rehabilitation: an illustration of appropriate statistical analyses. *Clin Rehabil* 1998; 12:187–199.
15. Bland JM, Altman DG. Applying the right statistics: analyses of measurement studies. *Ultrasound Obstet Gynecol* 2003; 22:85–93.
16. Bland JM, Altman DG. Measuring agreement in method comparison studies. *Stat Methods Med Res* 1999; 8:135–160.
17. Dietz HP. Clinical consequences of levator trauma. *Ultrasound Obstet Gynecol* 2012; 39:367–371.
18. Dietz HP, Gillespie AV, Phadke P. Avulsion of the pubovisceral muscle associated with large vaginal tear after normal vaginal delivery at term. *Aust NZ J Obstet Gynaecol* 2007; 47:341–344.
19. Volloyhaug I, Wong V, Shek KL, Dietz HP. Does levator avulsion cause distension of the genital hiatus and perineal body? *Int Urogynecol J* 2013; 24:1161–1165.
20. Dietz HP. Pelvic floor trauma following vaginal delivery. *Curr Opin Obstet Gynecol* 2006; 18:528–537.
21. Dietz HP, Hyland G, Hay-Smith J. The assessment of levator trauma: a comparison between palpation and 4D pelvic floor ultrasound. *Neurourol Urodyn* 2006; 25:424–427.